

HYALURONIDASE ACTIVITY OF THE URINE IN NECROTIC NEPHROSIS

L. N. Ivanova

From the Department of Physiology (Director – Corresponding Member of the Acad. Med. Sci. USSR A. G. Ginetsinsky) Novosibirsk Medical Institute (Director – Professor G. D. Zalesky)

(Received November 18th, 1957. Presented by Academician L. A. Orbeli)

Various pathological conditions of the kidneys are accompanied by characteristic changes in the hyaluronidase activity of the urine [1]. Thus, during the acute stage of diffuse glomerular nephritis, the activity of the enzyme is considerably increased, and the transition to the chronic phase is marked by a change in the hyaluronidase-diuresis curve, while in lipoid and amyloid nephroses, the hyaluronidase activity is reduced or even absent.

In the present investigation we studied the changes in hyaluronidase activity in experimentally induced necrotic nephrosis.

EXPERIMENTAL METHOD

Necrotic nephrosis was induced in dogs using Bobei's method [2] with subcutaneous injections of a 1% solution of uranium nitrate (2 mg per kg).

Symptoms were manifested most intensely one week after the injections. The general condition of the animal deteriorated, and signs of uremia appeared. Kidney function was reduced (urea clearance was 2.48 ml/minute/m², ie. it fell to 5% of the normal figure).

The protein content of the urine rose to 6.6%, and in the sediment hyaline casts and amorphous epithelial debris were found.

EXPERIMENTAL RESULTS

The results of the urine tests for hyaluronidase activity are shown in Fig. 1.

In the dog poisoned with uranium nitrate, the hyaluronidase activity is somewhat higher than normal. With a small diuresis it has a value of 30-33 units instead of the normal 20, and when the excretion rate reaches 1 ml per minute, when normally the activity falls to zero, it remains at a level of 20 units. No hyaluronidase activity was detected in the blood plasma.

The dog was killed two weeks after the injection. A histological investigation of the kidney confirmed a diagnosis of necrotic nephrosis.

We were also able to follow the changes in the hyaluronidase activity of the urine in kidney damage of the necrotic nephrosis type occurring in a human patient as a result of poisoning with corrosive sublimate.

The young woman, aged 19, was admitted to the town clinic hospital on December 13th, 1954 with hematemesis, and complaining of severe headache and a burning sensation in the mouth and esophagus. On that day she had drunk 150 ml of a solution of corrosive sublimate, intending to commit suicide.

Investigations were started 9 days after taking the poison. By that time the patient's condition was very grave, and there were clearly marked signs of nephrosis, stomatitis, colitis and cystitis.

The concentration of urea in the blood rose to 444 mg %. The urine, of which 900 ml were voided daily, was turbid and had the high protein content of 2.64%; in the sediment there were a number of leukocytes, hyaline casts, and various epithelial cells. Renal function was considerably reduced — the urea clearance was only 1.5 ml/minute, i.e. 3.6% of normal, while the concentration index of the urea at a diuresis of 0.74 ml/minute had a value of 1.8.

A bilateral decapsulation of the kidneys was carried out as one of the measures adopted to combat the anuria. During the operation, a portion of the capsule together with some adherent renal tissue was taken for histological examination. There was a necrosis and desquamation of the epithelium of the convoluted tubules with minimal changes in the glomeruli, shown by a hyperemia, thus indicating a severe nephrosis of the necrotic type (Fig. 2).

The hyaluronidase activity was determined with a viscometric method in each spontaneously voided sample of urine.

As can be seen from Fig. 3, the hyaluronidase activity of the urine was markedly increased. At a diuresis of 0.3-0.5 ml/minute/ m^2 it reached a value of 33 units, falling to 12-17 units when diuresis increased, and maintaining this value subsequently. Thus in the patient with necrotic nephrosis the hyaluronidase activity was higher than in a healthy human subject.

No increase in the hyaluronidase activity in the blood plasma was found.

This very limited material does not allow us to reach any definite conclusion about the reasons for the change in the hyaluronidase activity of the urine in necrotic nephrosis. The effect would appear to be due to the destruction of renal tissue setting free the enzyme contained in the cells.

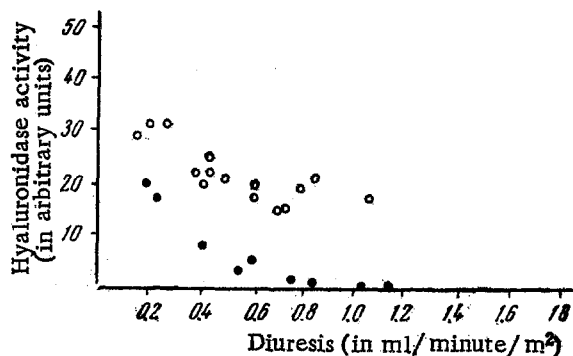


Fig. 1. Changes in the hyaluronidase activity of the urine in a dog poisoned with uranium nitrate; ● — hyaluronidase activity of the urine before poisoning; ○ — hyaluronidase activity of the urine in the same dog 1 week after poisoning.




Fig. 2. Section through kidney of patient with corrosive sublimate poisoning (magnification 280 times).

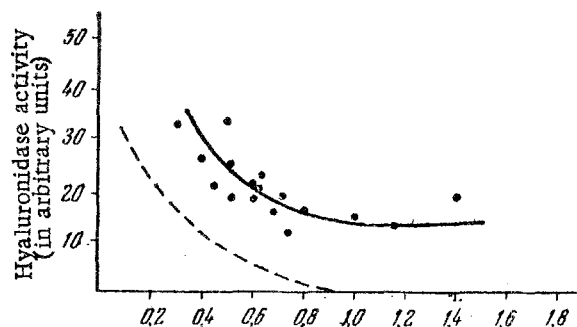


Fig. 3. Hyaluronidase activity of the urine in patient with corrosive sublimate poisoning. Dotted line shows curve of hyaluronidase activity against diuresis for healthy human subject.

SUMMARY

In kidney damage in man due to corrosive sublimate poisoning, the activity of hyaluronidase in the urine is considerably increased. The same increase in the enzymatic activity is observed in urine of dogs which were subjected to the effect of uranium salts. It is quite probable that the increased hyaluronidase activity in urine is due to the destruction of the elements of kidney tissue which liberate the enzymes in necrotic nephrosis.

LITERATURE CITED

- [1] A. G. Ginetsinsky, A. Ya. Broitman and L. N. Ivanova, *Byull. Eksptl. Biol. i Med.*, 38, 8, 37-39 (1954).
- [2] M. Bobey, L. Longley, R. Dicher, G. Price and G. Hagman, *Amer. J. Physiol.*, 139, 155-160 (1943).